

# Investigation of eligible heart rate for full reconstruction during coronary computed tomography angiography using 320-row area detector computed tomography with high-speed rotation

Daisuke Shibata, MD, Hiroshi Toyama, MD, PhD

Department of Radiology, School of Medicine, Fujita Health University, Aichi, Japan

## Abstract

**Objectives:** In coronary computed tomography angiography (CCTA), half reconstruction has commonly been used to prioritize temporal resolution. With the latest 320-row area detector computed tomography (ADCT), the maximum tube rotation speed has been increased to 0.275 s/rotation, and full reconstruction could be used to improve image quality at low heart rate. We compared motion artifacts on full-reconstruction CCTA images with half-reconstruction images and investigated the heart rate at which full reconstruction might be indicated.

**Methods:** Among the 162 consecutive patients who underwent CCTA using 320-row ADCT at our hospital, 50 with a regular pulse and  $\leq 60$  bpm heart rate during imaging were included. Half-reconstruction and full-reconstruction images were created from the imaging data. Motion artifacts were visually assessed on a five-point scale, and the two image types were compared.

**Results:** Comparison between half-reconstruction and full-reconstruction images from all of the subjects with heart rate of  $\leq 60$  bpm indicated that motion artifacts were considerably more common in the latter. No statistically significant difference was found between the two image types from subjects with heart rate  $< 50$  bpm.

**Conclusion:** If ADCT with a faster tube rotation speed is used for CCTA, full reconstruction of images might be indicated in patients with heart rate  $< 50$  bpm.

**Keywords:** 320-row area detector computed tomography (ADCT), coronary artery, full reconstruction, motion artifact

## Introduction

In recent years, coronary computed tomography angiography (CCTA) has become a popular tool for diagnosing ischemic heart disease. It is widely used to assess the presence of stenosis, and it is useful for evaluating three-dimensional information and the shape of arterial plaques.<sup>1,6</sup>

Because CCTA is used to image moving objects, half reconstruction has commonly been used.<sup>7</sup> Half reconstruction offers superior temporal resolution because approximately 180° of data are captured during one tube rotation. However, compared with full reconstruction, which uses the full 360° of data per rotation, decreased data volume with half reconstruction makes image inferiority unavoidable. Although full reconstruction could improve the uniformity of images and decrease tube position-dependent artifacts, these advantages are outweighed by the influence of motion artifacts caused by decreased temporal resolution. Therefore, this method has not been put into practical use.

The Aquilion ONE Vision edition (Toshiba Medical Systems, Tochigi, Japan) is the latest 320-row area detector computed tomography (ADCT) device. It offers improved temporal resolution by increasing the maximum tube rotation speed to 0.275 s/rotation. It is anticipated that, with this device, full reconstruction could be used in patients with low heart rate. However, few reports have investigated whether full reconstruction for CCTA using ADCT with increased tube rotation speed is indicated in such cases.<sup>8</sup>

We evaluated motion artifacts in full-reconstruction images obtained with CCTA using ADCT with increased tube rotation speed to identify the heart rate at which full reconstruction might be indicated.

## Methods

The Ethical Review Board for Epidemiological and Clinical Studies of the Fujita Health University approved this retrospective study.

### Patients

Of 162 consecutive patients who underwent CCTA using 320-row ADCT at our university hospital between June and October 2012, there were 50 patients with a sinus rhythm and a heart rate  $\leq 60$  bpm. They were included in this study. The study group thus included 40 men and 10 women with a mean age of 65 years and a mean weight of 63 kg. Other data included a mean heart rate of 53 bpm, mean computed tomography dose index (CTDI) of 69.3, and a mean dose length product (DLP) of 462.5. The values calculated with the CT equipment were used as references for the radiation exposure indices CTDI and DLP.

### Devices and imaging conditions

Aquilion ONE Vision edition CT equipment was used. Scans were performed using nonhelical scanning, in which images are taken without transposition of the tube or the berth. The tube rotation time was set at 0.275 s/rotation and the tube voltage at 120 kV or 135 kV. The tube current was set with a designated image-noise standard deviation of 27.5 using the automatic exposure control function<sup>9</sup> (tube current 170–750 mA). The prospective CTA mode<sup>10</sup> was used, and the

Received 3 June 2015, Accepted 4 August 2015

Corresponding author: Daisuke Shibata, MD

Department of Radiology, School of Medicine, Fujita Health University, 1-98 Dengakugakubo, Kutsukake-cho, Toyoake, Aichi 470-1192, Japan

E-mail: dshibata@fujita-hu.ac.jp

exposure cardiac phase during electrocardiography (ECG)-gated volume scanning was based on 70-80% of an R-R interval. The imaging range (imaging rows) was set at the minimum range from the origin to the peripheries of the coronary artery, with reference to plain CT images obtained directly before imaging to measure the calcium score. The imaging slice thickness was 0.5 mm, and the reconstruction interval was 0.25 mm. For reconstruction, after determining the best static cardiac phase (determined absolute time), half-reconstruction and full-reconstruction images were created for that phase and compared. Images were observed on a Toshiba FX Report system viewer, and multiplanar reconstruction images created from volume data were used.

#### Contrast protocol and pretreatment

The contrast medium included iodine at a concentration of 300 or 370 mg I/mL. Our contrast medium had a concentration of 20.4 mg I/kg/s with a basic injection time of 12 s. It was followed by 20 mL of physiological saline solution. Scanning according to the bolus-tracking method<sup>11</sup> was started 13 s after injection of the contrast medium. The main scanning was started when the ascending aortic CT values reached 150 Hounsfield units (HUs). Prior to imaging, a sublingual spray of isosorbide dinitrate (Nitorol Spray<sup>®</sup>) was administered to all subjects to increase the length of the coronary artery segments that could be evaluated. Unless contraindicated, intravenous landiolol hydrochloride (Corebeta<sup>®</sup>) was administered to control the heart rate as necessary (12 of the 50 subjects).

#### Investigated items

We investigated whether there was a correlation between evaluation points and the heart rate. We also examined the concordance rate of the evaluation points among the evaluators. Motion artifacts in the main coronary trunk were compared by visual evaluation of half-reconstruction and full-reconstruction images. In all, three evaluators—two radiologists (with 7 and 3 years of experience in radiological diagnosis, respectively) and one radiological technician (with 5 years of experience)—separately performed the visual evaluation. Visual evaluation was scored on a 5-point scale: images with no motion artifacts, 5 points; images with motion artifacts but the blood vessel shape was maintained, 3 points; images in which the shape was not maintained, 1 point; images that fell between two categories, assigning either 4 or 2 points, respectively. Image elements other than motion artifacts were not evaluated in this study.

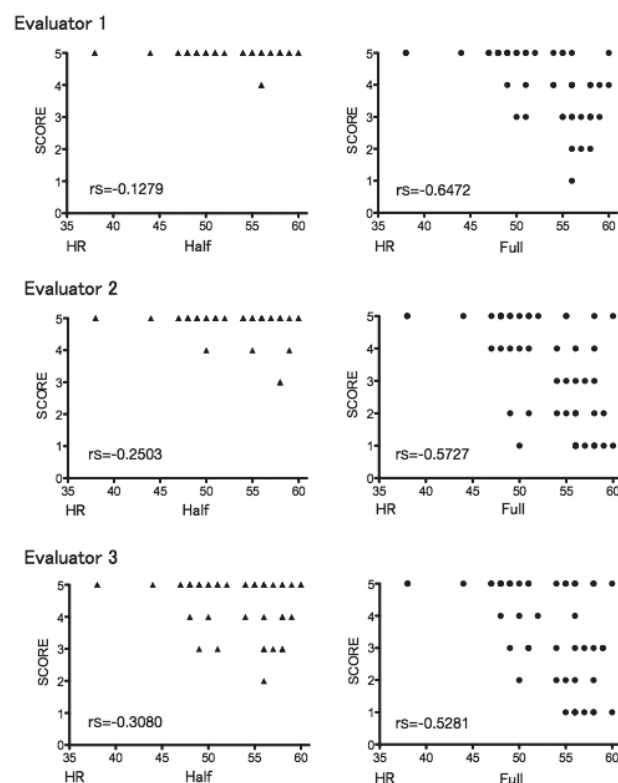
#### Statistical analysis

Spearman's rank correlation coefficients were used to analyze the correlation between evaluation points and the heart rate. Kendall's coefficient of concordance was calculated to determine the concordance rate for the evaluation points among evaluators. Each evaluation point between reconstruction algorithms was compared using Wilcoxon's signed-rank test. The level of significance was set at 5%.

## Results

The relation between evaluation points and the heart rate for each evaluator is shown in Figure 1. The comparison of evaluation points between reconstruction algorithms is shown in Table 1. Test results of the concordance rate for evaluation points among evaluators are shown in Table 2. For the half-reconstruction images, no or only a weak correlation was observed between the heart rate and evaluation points for all evaluators ( $r_s = -0.1279$  to  $-0.3080$ ). The extent of motion artifacts was consistently low regardless of the heart rate. For full-reconstruction images, a negative correlation was observed between the heart rate and evaluation points for all evaluators ( $r_s = -0.5281$  to  $-0.6472$ ). Also, the level of motion artifacts increased as the heart rate increased (Figure 1). Evaluation points between the reconstruction algorithms were as follows: evaluator 1: 5.0 vs. 4.0 (ranges 5.0-5.0 and 3.0-5.0, respectively;  $P < 0.0001$ ); evaluator 2: 5.0 vs. 4.0 (ranges 5.0-5.0 and 2.0-5.0, respectively;  $P < 0.0001$ ); evaluator 3: 5.0 vs. 4.0 (ranges 4.0-5.0 and 2.0-5.0, respectively;  $P < 0.0001$ ). Thus, according to all three evaluators, there were significantly more motion artifacts in full-reconstruction images (Table 1). Investigation of the concordance rate for evaluation points indicated a low concordance rate for half-reconstruction images ( $\tau = 0.419$ ,  $P = 0.108$ ) and a high concordance rate for full-reconstruction images ( $\tau = 0.857$ ,  $P < 0.0001$ ) (Table 2).

Figure 1



Relation between the evaluation points and heart rate for each evaluator. The number of artifacts was uniformly low for half-reconstruction images as determined by all evaluators regardless of heart rate. For full-reconstruction images, however, the extent of motion artifacts tended to increase as the heart rate increased.

Table 1. Comparison of evaluation points between reconstruction algorithms

	Half	Full	P value
Evaluator 1	5.0 (5.0-5.0)	4.0 (3.0-5.0)	<0.0001
Evaluator 2	5.0 (5.0-5.0)	4.0 (2.0-5.0)	<0.0001
Evaluator 3	5.0 (4.0-5.0)	4.0 (2.0-5.0)	<0.0001
	median(IQR)	median(IQR)	

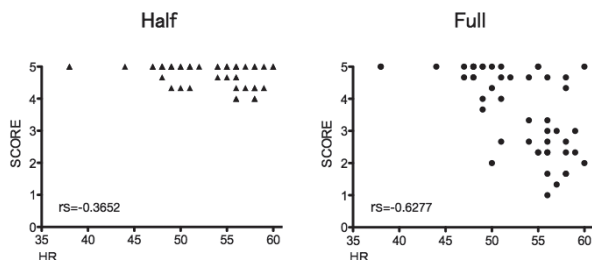
IQR: Interquartile Range

Table 2. Results of statistical tests regarding the rate of concordance for evaluation points among evaluators

	Half	Full
Kendall W	0.419	0.857
P value	0.108	<0.0001

The mean scores of the three evaluators for half-reconstruction images and full-reconstruction images, their relation to the heart rate, and inter-algorithm comparisons are shown in Figure 2, Figure 3, and Table 3, respectively. For the half-reconstruction images, there was a very weak negative correlation between the heart rate and evaluation points ( $r_s = -0.3652$ ). However, artifacts were infrequent in all subjects. For full-reconstruction images, there was a negative correlation between the heart rate and evaluation points ( $r_s = -0.6277$ ). Additionally, as with the comparison between evaluators, the level of motion artifacts was noted to increase as the heart rate increased (Figure 2). Investigation of evaluation points in all 50 subjects indicated that the median (interquartile range, or IQR) was 5.0 points (4.4-5.0) for half-reconstruction images and 4.2 points (2.4-5.0) for full-reconstruction images. The difference in the extent of motion artifacts between the two image types was significant ( $P < 0.0001$ ). However, when the patients were restricted according to their heart rate and compared again, the differences in the evaluation points between the two image types tended to decrease with lower heart rate. Comparison of the images of the 15 patients whose heart rate was <50 bpm indicated that the significant difference in the extent of motion artifacts between image types disappeared, with a median (IQR) of 5.0 points (5.0-5.0) for half-reconstruction images and 5.0 points (4.7-5.0) for full-reconstruction images ( $P = 0.0975$ ) (Figure 3, Table 3).

Figure 2



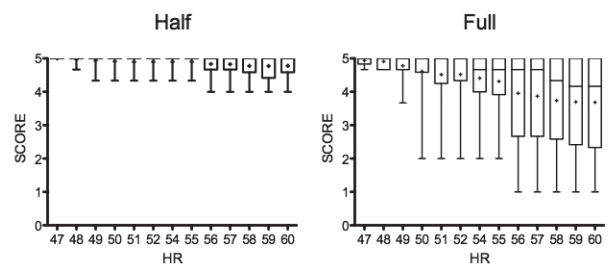
Relation between the mean evaluation points of the evaluators and the heart rate for each reconstruction algorithm. For half-reconstruction images, the extent of artifacts was low for all subjects. For full-reconstruction images, however, the extent of motion artifacts tended to increase as the heart rate increased.

Table 3. Comparison of evaluation points between reconstruction algorithms according to the heart rate

	Half	Full	P value
<60 bpm (n=50)	5.0 (4.4-5.0)	4.2 (2.4-5.0)	$P < 0.0001$
<49 bpm (n=15)	5.0 (4.7-5.0)	5.0 (4.7-5.0)	ns
	median(IQR)	median(IQR)	

IQR: Interquartile Range

Figure 3



Relation between the mean evaluation points of the evaluators and the heart rate for each reconstruction algorithm. For patients with a high heart rate, there was a significant difference regarding the extent of motion artifacts between the two image types. This difference, however, narrowed as the heart rate decreased. Also, the statistically significant difference between the image types disappeared when the heart rate was <50 bpm.

### Discussion

To investigate the heart rate at which the full-reconstruction algorithm can be applied, we compared motion artifacts in full-reconstruction images obtained with CCTA imaging using ADCT with a rotation speed increased to 0.275 s/rotation to those in half-reconstruction images (the most commonly used image type), at the same rotation speed. We demonstrated that there was no significant difference in motion artifacts between full-reconstruction and half-reconstruction images in subjects with a low heart rate.

Patients in this study were limited to those with a sinus rhythm and a heart rate of ≤60 bpm—at which rate good static images could be obtained with 320-row ADCT.<sup>12</sup> Because conventional half-reconstruction images received high scores in all patients, we believe that this study has validity. For full-reconstruction images, a correlation was observed between the heart rate and motion artifacts, with the level of artifacts decreasing as the heart rate decreased. These results are consistent with those reported by Takayanagi et al.<sup>8</sup> Except for those with a high heart rate, CCTA imaging and reconstruction are generally performed during the mid-diastolic phase—the slow-filling (SF) phase—which is the cardiac phase with the least heart movement.<sup>12-15</sup> Theoretically, if the SF phase is longer than the temporal resolution of the imaging device, good static images can be obtained. Sano et al.<sup>16</sup> reported that the SF phase has a significant positive correlation with the difference between the R-R and P-Q intervals. This is consistent with the correlation noted in this study between the heart rate and visual evaluation of motion artifacts. Temporal resolution in full reconstruction images is identical to the gantry rotation time.<sup>17</sup> The ADCT temporal resolution used in this study was 275 ms. According to calculations, if the R-R interval is ≥ 1168 ms, the SF phase is >275 ms.<sup>16</sup> If this R-R interval is converted to the heart rate, it is equivalent to approximately 51 bpm. This rate is close to the 50 bpm (R-R = 1200 ms) observed in this study as the threshold heart rate at which the significant difference in motion artifacts disappeared in comparison with the conventional method.

The visual evaluation points were consistent among all evaluators for full-reconstruction images. For the half-reconstruction images, however, there was a low concordance rate. Although the full-reconstruction images included images of varying quality, ranging from static images to those with strong motion artifacts, the concordance rate among evaluators

was good, suggesting that there was consensus regarding the evaluation criteria. For half-reconstruction images, however, inconsistency was demonstrated because the concordance rate among evaluators was low despite motion artifacts being present to a uniformly low extent in these images. These results suggest that other factors may be involved in lower scores, such as the influence of methods of setting target vessels for evaluation and differences in image quality. With CCTA, the target vessel for evaluation is often divided into 15 segments according to the guidelines of the American Heart Association.<sup>18-20</sup> In this study, however, the main coronary artery was comprehensively evaluated and scored for each patient. Hence, even half-reconstruction images that had few overall motion artifacts may have evaluation point differences because of the difference between evaluators within a partial artifact permissible range. With regard to differences in image quality, although approximately twofold temporal resolution is achieved in exchange for using only a 180° + fan angle/360° with the half-reconstruction method, data projected from 360° are used with the full-reconstruction method. As a result, approximately twice the amount of data are used for full-reconstruction compared with half-reconstruction, thereby decreasing the amount of noise and tube position-dependent artifacts. Thus, the image quality other than motion artifacts of the half-reconstruction images is overwhelmingly inferior to that of the full-reconstruction images. When evaluating the half-reconstruction images, the motion artifacts may have been mixed with other image quality-degradation elements. If so, it may have made evaluation difficult, causing the lack of consistency among evaluators. When evaluating the full-reconstruction images, the improved image quality made the motion artifacts stand out, which consequently made evaluation easy. This may have been the reason for the good concordance rate among evaluators in this area.

This study demonstrated that the heart rate is an important factor for determining the presence of motion artifacts. Underlying heart disease and cardiac function, however, must also be considered as factors that could affect cardiac artery movement and the heart rate. The ability to hold one's breath and the presence or absence of body movement can also be important factors related to motion artifacts. However, because we investigated only the heart rate in this study, these other factors need to be investigated in the future.

The only disadvantage of full-reconstruction images is that motion artifacts arise when temporal resolution is insufficient. As full-reconstruction images are superior in regard to all other factors that determine image quality compared with half-reconstruction images, full reconstruction should be used whenever possible. In this study, we demonstrated that, even in full-reconstruction images, motion artifacts can be decreased when the heart rate is low, and full reconstruction can be applied to patients with heart rate <50 bpm.

In conclusion, we investigated the indications for full-image reconstruction during CCTA using ADCT with an increased rotation speed (0.275 s/rotation). The results demonstrated that if the heart rate is ≤ 50 bpm, motion artifacts have little influence on the images, and clinical application is possible.

## Acknowledgements

We are deeply grateful to everyone in the Departments of Cardiovascular Medicine and Cardiovascular/Respiratory Surgery at Fujita Health University for the valuable advice

they provided. We also thank everyone at the Fujita Health University Department of Radiology, and the Department of Radiology at the Fujita Health University Hospital for cooperating and offering advice when performing CCTA.

## Conflict of interests

The authors declare no conflicts of interest associated with this manuscript.

## References

- Budoff MJ, Liu S, Chow D, Flores F, Hsieh B, Gebow D, DeFrance T, Ahmadi N. Coronary CT angiography versus standard of care strategies to evaluate patients with potential coronary artery disease: effect on long term clinical outcomes. *Atherosclerosis* 2014;237:494-8.
- Chow BJ, Abraham A, Wells GA, Chen L, Ruddy TD, Yam Y, Govas N, Galbraith PD, Dennie C, Beanlands RS. Diagnostic accuracy and impact of computed tomographic coronary angiography on utilization of invasive coronary angiography. *Circ Cardiovasc Imag* 2009;2:16-23.
- Van Velzen JE, Schuijff JD, de Graaf FR, Boersma E, Pundziute G, Spanó F, Boogers MJ, Schalij MJ, Kroft LJ, de Roos A, Jukema JW, van der Wall EE, Bax JJ. Diagnostic performance of non-invasive multidetector computed tomography coronary angiography to detect coronary artery disease using different endpoints: detection of significant stenosis vs. detection of atherosclerosis. *Eur Heart J* 2011;32:637-45.
- Tomizawa N, Hayakawa Y, Nojo T, Nakamura S. Improving the diagnostic performance of the real world coronary computed tomography angiography including uninterpretable segments. *Int J Cardiol* 2014;176:975-9.
- Motoyama S, Kondo T, Anno H, Sugiura A, Ito Y, Mori K, Ishii J, Sato T, Inoue K, Sarai M, Hishida H, Narula J. Atherosclerotic plaque characterization by 0.5-mm-slice multislice computed tomographic imaging. *Circ J* 2007;71:363-6.
- Motoyama S, Kondo T, Sarai M, Sugiura A, Harigaya H, Sato T, Inoue K, Okuma K, Ishii J, Anno H, Virmani R, Ozaki Y, Hishida H, Narula J. Multislice computed tomographic characteristics of coronary lesions in acute coronary syndromes. *J Am Coll Cardiol* 2007;50:319-26.
- Abbara S, Arbab-Zadeh A, Callister TQ, Desai MY, Manuya W, Thomson L, Weigold WG. SCCT guidelines for performance of coronary computed tomographic angiography: a report of the Society of Cardiovascular Computed Tomography Guidelines Committee. *J Cardiovasc Comput Tomogr* 2009;3:190-204.
- Takayanagi T, Sano T, Kondo T, Amanuma M, Ishizuka K, Sekine T, Matsutani H, Morita H, Arai T, Takase S. Clinical usefulness of low tube current scanning with full reconstruction in a prospective ECG-gated coronary angiography using 320-row area detector CT. *Nihon Hoshasen Gijutsu Gakkai Zasshi* 2015;71:237-45 (in Japanese).
- Shirasaka T, Funama Y. Influence of maximum tube current threshold in automatic exposure control at 64-detector row CT: relationship between radiation dose reduction rate and variability of image noise. *Nihon Hoshasen Gijutsu Gakkai Zasshi* 2009;65:295-300 (in Japanese).
- Shinno T. Element technology for area detector CT-aquilion ONE. *Nihon Hoshasen Gijutsu Gakkai Zasshi* 2008;64:734-43 (in Japanese).
- Yamaguchi T, Takahashi D. Development of test bolus tracking method and usefulness in coronary CT angiography. *Nihon Hoshasen Gijutsu Gakkai Zasshi* 2009;65:1032-40 (in Japanese).
- Sano T, Matsutani H, Kondo T, Fujimoto S, Sekine T, Arai T, Morita H, Takase S. Estimation of radiation dose and image quality of coronary 320-row area detector CT angiography by optimal prospective ECG-gated protocols for different heart rate. *Nihon Hoshasen Gijutsu Gakkai Zasshi* 2011;67:1398-407 (in Japanese).
- Leschka S, Husmann L, Desbiolles LM, Gaemperli O, Schepis T, Koepfli P, Boehm T, Marincek B, Kaufmann PA, Alkadhi H. Optimal image reconstruction intervals for non-invasive coronary angiography with 64-slice CT. *Eur Radiol* 2006;16:1964-72.
- Nagatani Y, Takahashi M, Takazakura R, Nitta N, Murata K, Ushio N, Matsuo S, Yamamoto T, Horie M. Multidetector-row computed tomography coronary angiography: optimization of image reconstruction phase according to the heart rate. *Circ J* 2007;71:112-21.
- Runza G, La Grutta L, Alaimo V, Damiani L, La Fata A, Alberghina F, Galia M, Lo Re G, Luccichenti G, Bartolotta T, Cademartiri F, Midiri M, De Maria M, Lagalla R. Influence of heart rate in the selection of the optimal reconstruction window in routine clinical multislice coronary angiography. *Radiol Med* 2008;113:644-57.
- Sano T, Kondo T, Matsutani H, Morita H, Arai T, Sekine T, Takase S, Oida A, Fukazawa H, Kodama T, Kondo M, Orihara T, Yamada N, Narula J. Significance of PQ interval in acquisition of coronary multidetector row computed tomography. *J Cardiol* 2009;54:441-51.
- Schöndube H, Allmendinger T, Stierstorfer K, Bruder H, Flohr T. Temporal

- resolution and motion artifacts in single-source and dual-source cardiac CT. *Med Phys* 2013;40:031112.
18. Ohashi K, Ichikawa K, Hara M, Kawai T, Kunitomo H, Higashide R, Shibamoto Y. Examination of the optimal temporal resolution required for computed tomography coronary angiography. *Radiol Phys Technol* 2013;6:453-60.
  19. Sun G, Li M, Jiang XS, Li L, Peng ZH, Li GY, Xu L. 320-Detector row CT coronary angiography: effects of heart rate and heart rate variability on image quality, diagnostic accuracy and radiation exposure. *Br J Radiol* 2012;85:e388-94.
  20. Tatsugami F, Matsuki M, Nakai G, Inada Y, Kanazawa S, Takeda Y, Morita H, Takada H, Yoshikawa S, Fukumura K, Narumi Y. The effect of adaptive iterative dose reduction on image quality in 320-detector row CT coronary angiography. *Br J Radiol* 2012;85:e378-82.

Copyright©2016 Daisuke Shibata, MD et al. 

This is an Open access article distributed under the Terms of Creative Commons Attribution License, which permits unrestricted use, distribution, and reproduction in any medium, provided the original author and source are credited.